



Clinical
Case Studies



RegenerOss[®] Xenografts





Table of Contents

RegenerOss Xenografts	
Product Information	4
Case 1: Mandibular Molar: Extraction, Grafting, and Implant Placement Seven Months Post-Op	6
Case 2: Maxillary Lateral Incisor: Extraction, Grafting, and Implant Placement Five Months Post-Op	7
Case 3: Mandibular Molar: Extraction, Grafting Followed by Immediate Implant Placement	8
Case 4: Mandibular Premolars: Extraction and Bone Grafting Followed with Dental Implant Placement at a Later Date	9
Ordering Information	10

RegenerOss Xenograft

Porcine Anorganic Bone Material

Carbonate Apatite Bone Graft Substitute¹

RegenerOss Xenograft is a porcine-derived carbonate apatite intended for bone repair and regeneration for oral surgical procedures.



Ideal Porous Osteoconductive Scaffold²

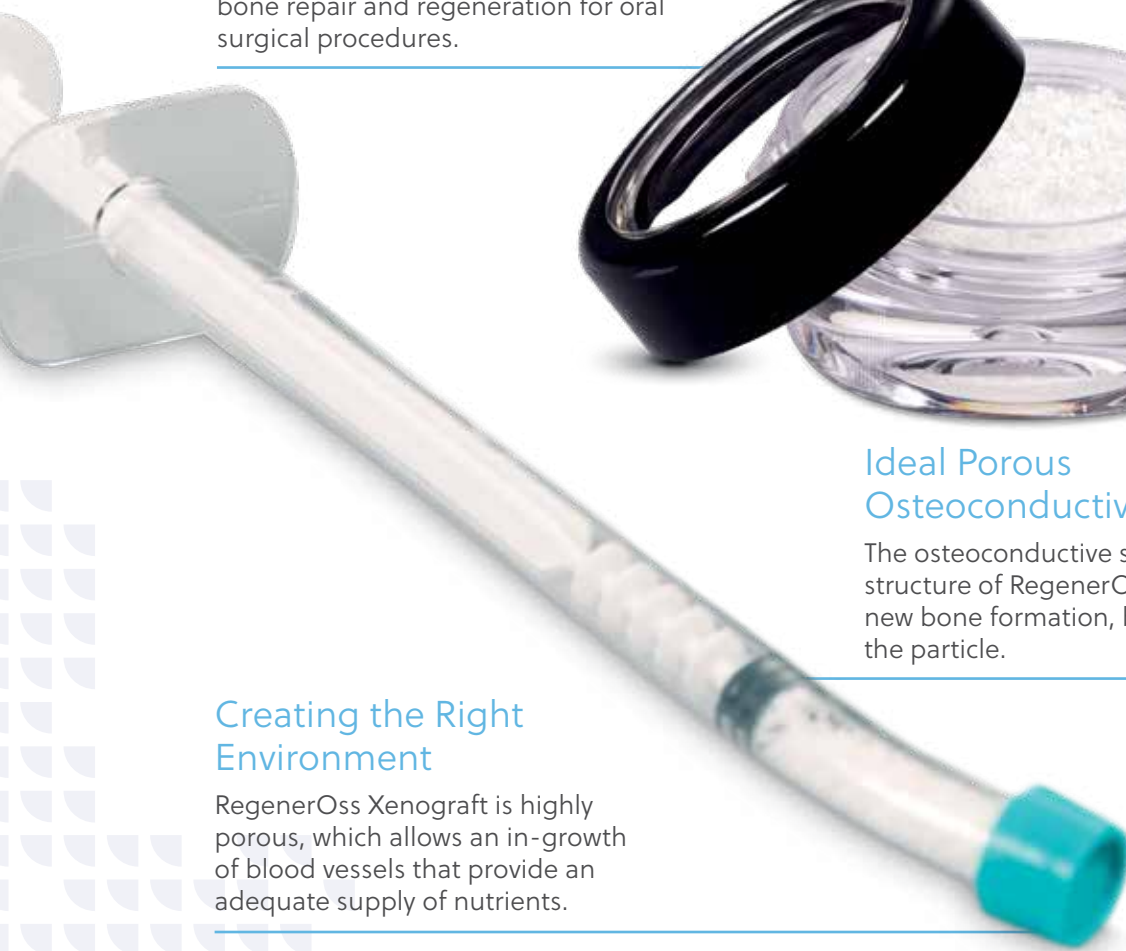The osteoconductive surface and porous structure of RegenerOss Xenograft allow for new bone formation, both around and within the particle.

Creating the Right Environment

RegenerOss Xenograft is highly porous, which allows an in-growth of blood vessels that provide an adequate supply of nutrients.

Easy to Use

Perforated cap is designed for easy hydration. Once fully hydrated, remove cap and deliver product to defect sites.



Bone Repair and Regeneration for Oral Surgical Procedures

- Provides an osteoconductive scaffold for bone regeneration due to its anorganic, porous structure
- Ideal option for alveolar ridge reconstruction, maxillary sinus floor elevation, filling of periodontal defects including infrabony defects and defects after root resection, cystectomy, and filling of extraction sockets

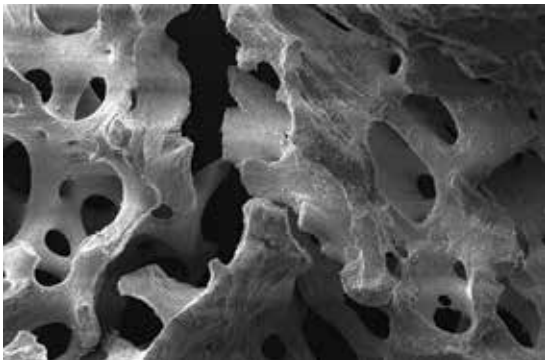
Natural Bone Carbonate Apatite Structure

- Carbonate apatite demonstrates better osteoconductive potential than hydroxyapatite^{3,4,5}
- Resorption and remodeling profiles are closer to natural bone than those of synthetic bone graft substitutes⁴


The Right Environment for Bone Regeneration

- High porosity means that space is maintained for new bone deposition
- Surface roughness allows for cellular adhesion and bone in-growth⁶

SEM of RegenerOss Xenograft



at x50

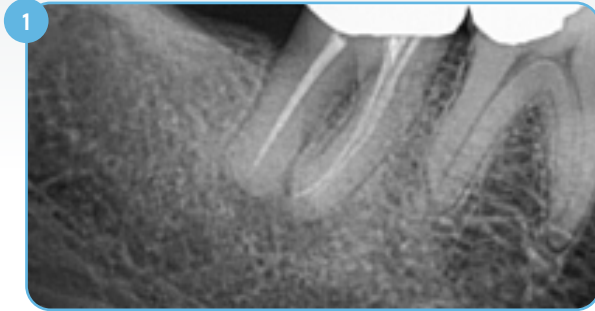


at x100

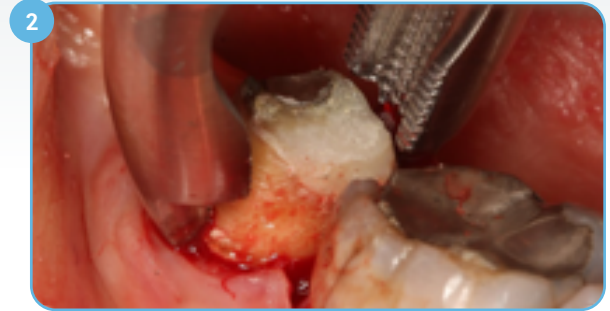
1. Data on file with Collagen Matrix, Inc.
2. Klenke FM1, Liu Y, Yuan H, Hunziker EB, Siebenrock KA, Hofstetter W. 2009. Impact of pore size on the vascularization and osseointegration of ceramic bone substitutes in vivo. *J Biomed Mater Res A* 85(3):777-86.
3. Spense G., Patel N., Brooks R., Rushton N. 2009. Carbonate Substituted Hydroxyapatite: Resorption by Osteoclasts Modifies the Osteoblastic Response. *Journal of Biomedical Materials Research Part A*.
4. Ellies LG, Carter JM, Natiella JR, Featherstone JDB, Nelson DGA. 1988. Quantitative Analysis of Early In Vivo Tissue Response to Synthetic Apatite Implants. *J Biomed Mater Res* 22:137-148.
5. Landi E., Celotti G., Logroscino G., Tampieri A. 2003. Carbonated Hydroxyapatite as Bone Substitute. *Journal of the European Ceramic Society* 23: 2931-2937.
6. Deligianni DD, Katsala ND, Koutsoukos PG, Missirlis YF, Effect of Surface Roughness of Hydroxyapatite on Human Bone Marrow Cell Adhesion, Proliferation, Differentiation and Detachment Strength. *Elsevier Biomaterials* 22 (2001) 87-96.

Case 1: Mandibular Molar

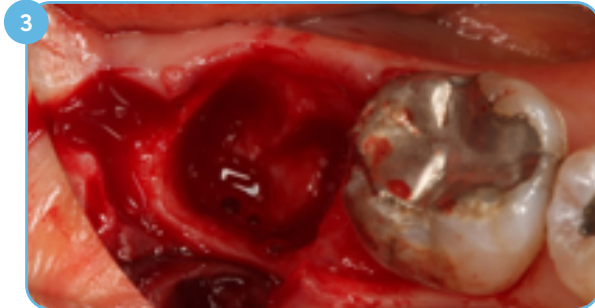
Extraction, Grafting, and Implant Placement 7 Months Post-Op



1 Preoperative radiograph revealing a suspected fracture. Partial loss of buccal plate due to repeated abscesses.



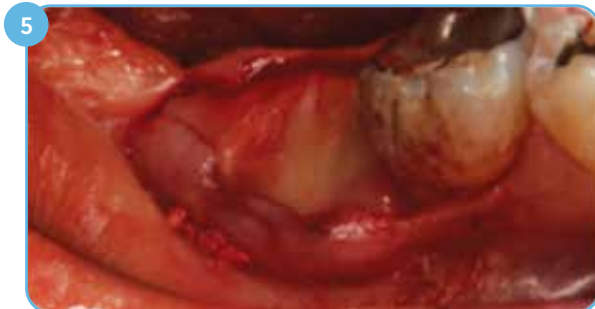2 Atraumatic extraction performed to preserve alveolar bone and thin buccal gingival tissue.



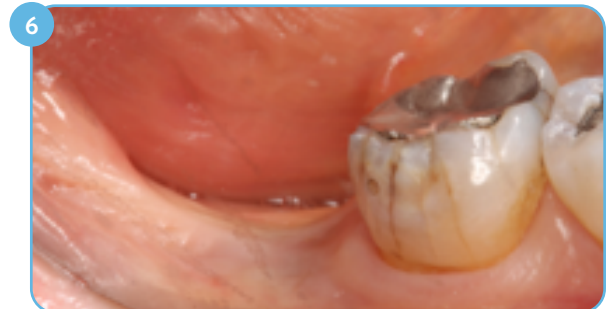3 Partial thickness elevation of buccal flap to assist in tissue closure.



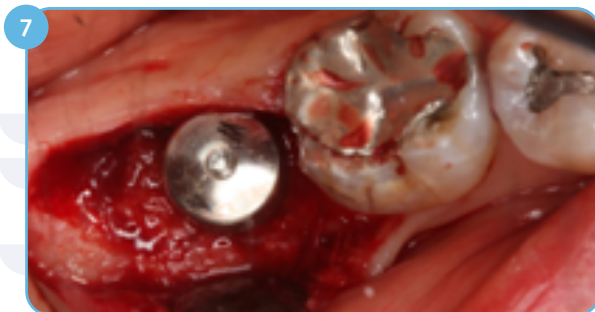4 RegenerOss Xenograft hydrated in the liquid expressed from preparation of L-PRF.



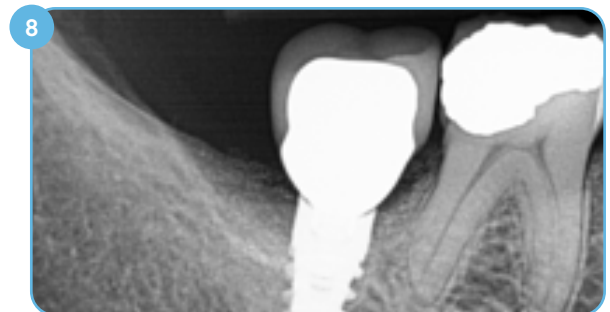
5 Socket grafted. A collagen membrane is placed over the grafted site.



6 Soft-tissue closure was observed at four weeks, and soft and hard tissues appear fully healed by six months.



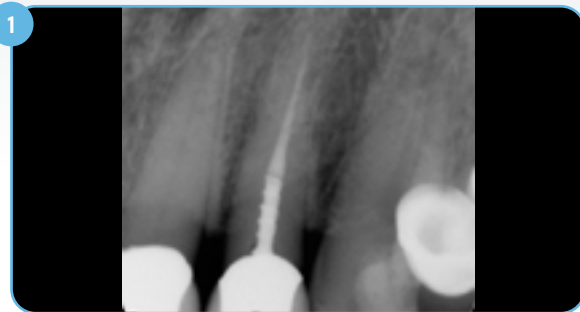
7 Seven months postoperatively, implant placed, 3+ mm thick keratinized tissue over site, Osstell® measurement of 89 on insertion.



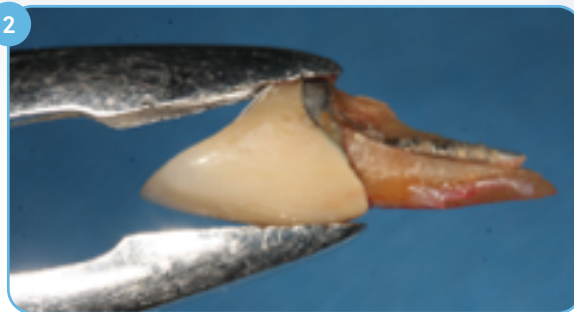8 Postoperative radiograph, six months after final restoration.

Case 2: Maxillary Lateral Incisor

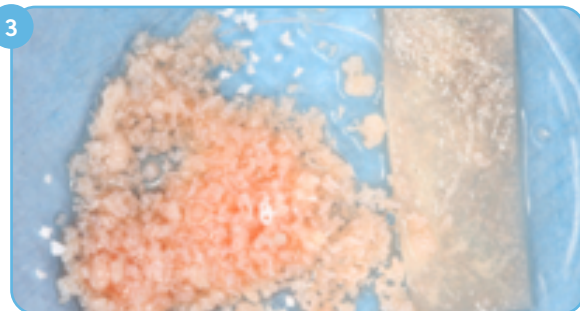
Extraction, Grafting, and Implant Placement 5 Months Post-Op



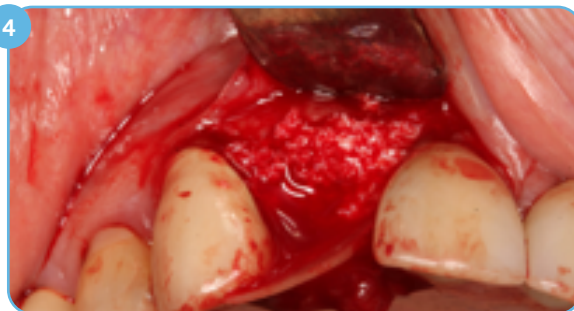1 Preoperative radiograph revealing fracture of the maxillary right lateral incisor.



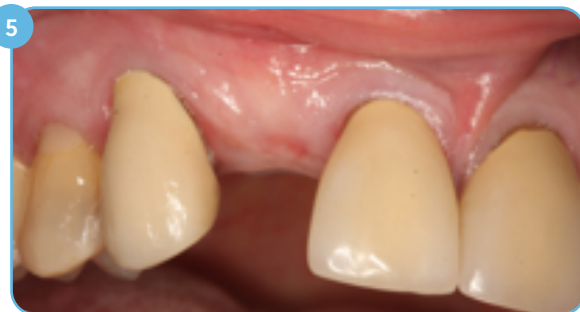2 The fractured coronal segment was removed and the rest of the root was extracted and the socket was debrided.



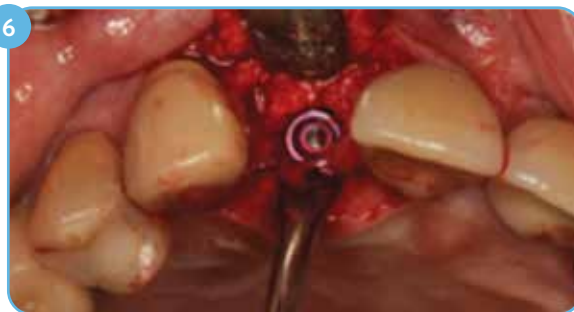3 The socket was grafted with RegenerOss Xenograft hydrated in L-PRF followed by placement of a collagen membrane.



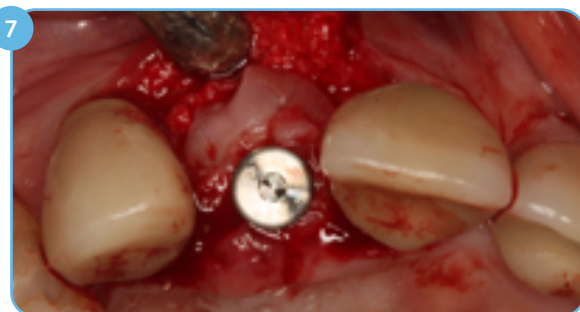4 After inserting the barrier under the facial flap, primary closure was obtained.



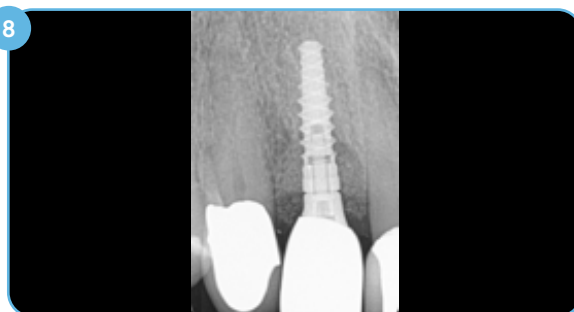5 The soft tissues were fully healed by four weeks postoperatively.



6 Seven weeks after extraction and grafting, an endosseous implant was placed to support a screw-retained crown.



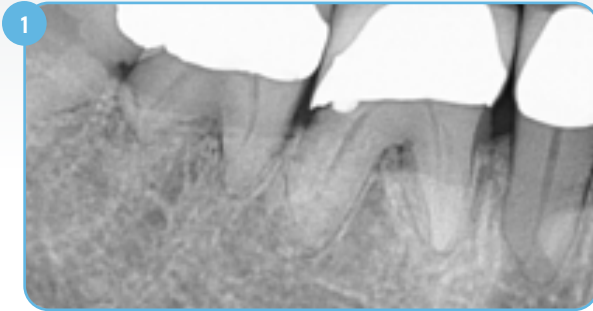
7 Five months after healing, the site was uncovered. The implant was fully stable. A PRF plug was placed around the healing abutment and the soft-tissue flaps were secured with intermittent sutures.



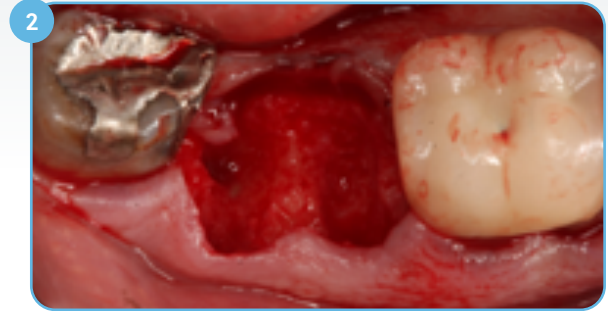8 Two-year postoperative radiograph showing stable bone level.

Case 3: Mandibular Molar

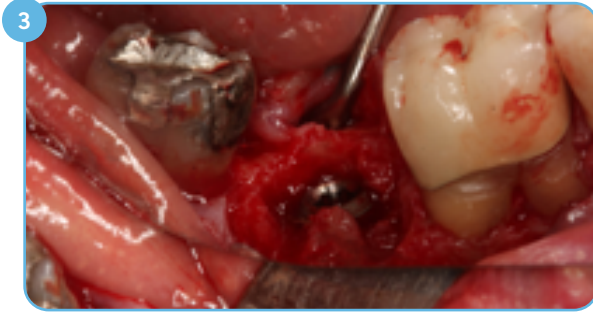
Extraction, Grafting Followed by Immediate Implant Placement



1 Preoperative radiograph showing periodontal recession, apical root resorption, and furcation involvement on teeth numbers 30 and 31.



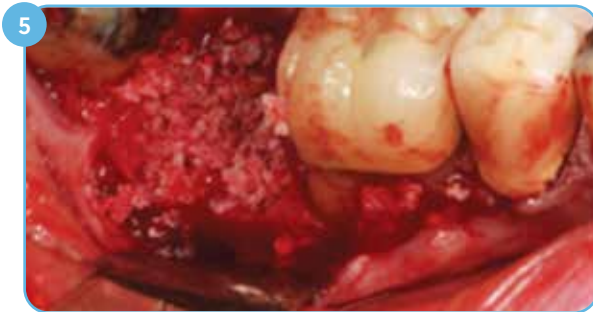2 Minimal flap elevation performed after atraumatic extraction of tooth number 31. The socket was debrided.



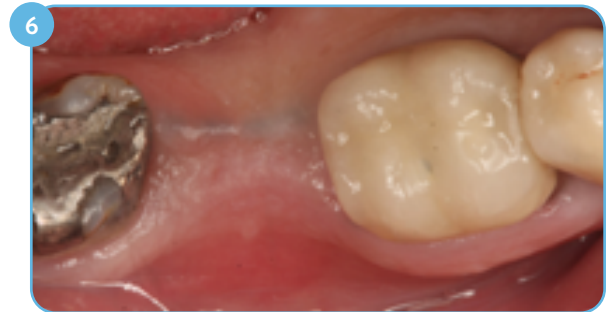
3 An implant was placed in site number 31. Roots were treated on the facial of tooth number 30 in preparation for osseous and periodontal grafting in the sextant.



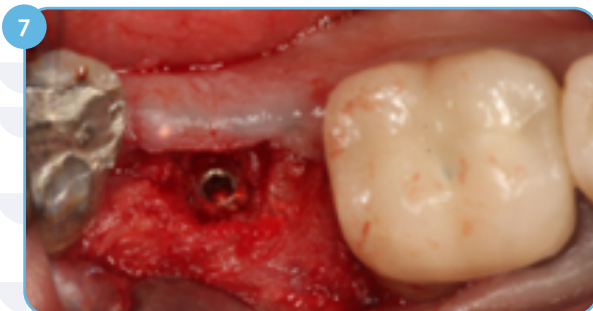4 RegenerOss Xenograft prior to hydration.



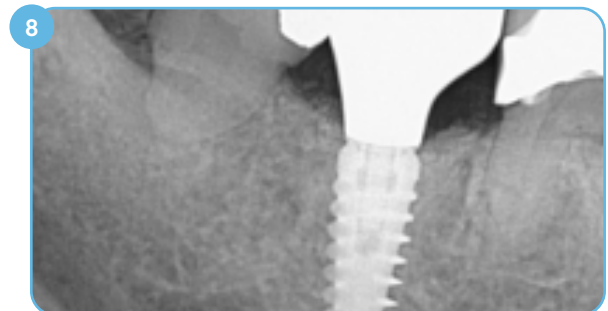
5 RegenerOss Xenograft hydrated in L-PRF and inserted in socket, buccal furcation and over the top of the newly inserted implant in site number 31.



6 Primary soft-tissue closure was accomplished and maintained in site number 31 throughout healing.



7 At uncovering, five months after implant insertion, 3 mm of regenerated tissue had to be removed from over the implant in site number 31.

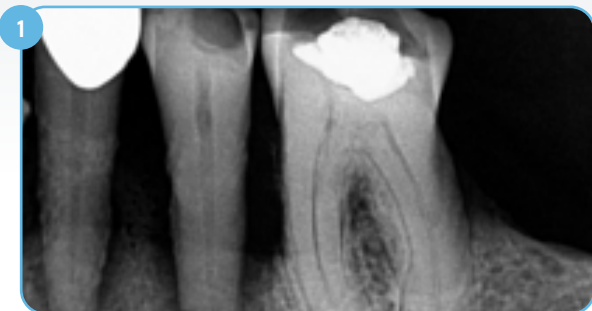

8 Postoperative radiograph showing screw-retained restoration at six months.

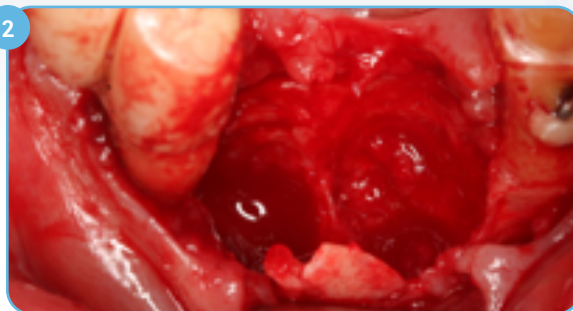Clinical photography courtesy of Robert A. Horowitz, DDS, Scarsdale, NY, USA

Case 4: Mandibular Premolars

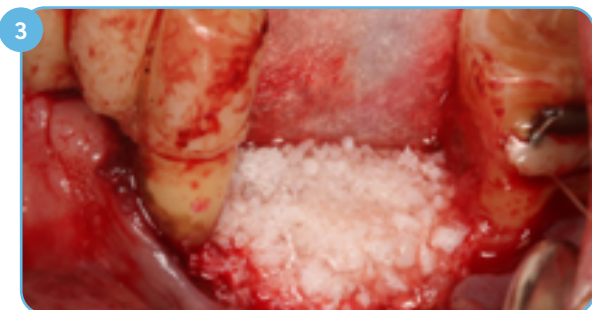Extraction and Bone Grafting Followed with Dental Implant Placement at a Later Date



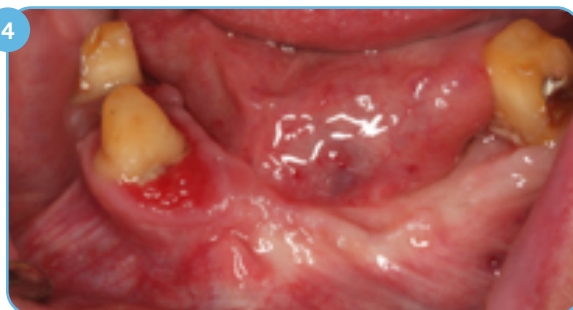1 Preoperative radiograph revealing large radiolucent areas around the roots of both premolar teeth.



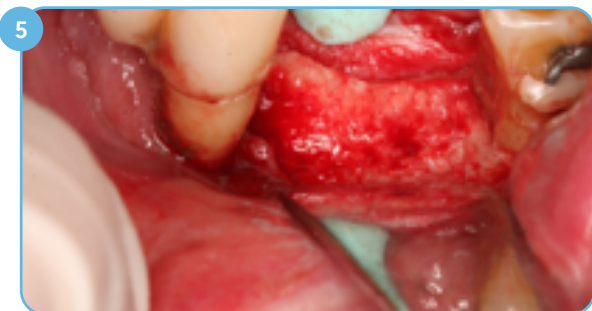2 Significant bone was lost interproximally and 5 – 8 mm of buccal alveolar plate was lost due to periodontal and endodontic infections.



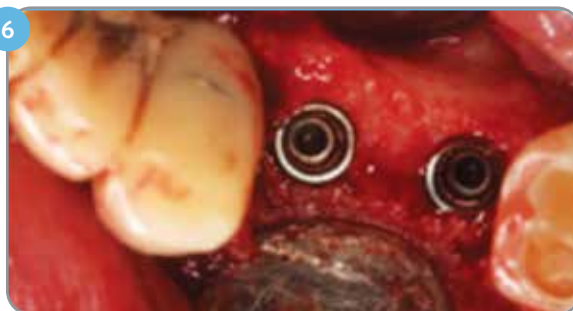3 RegenerOss Xenograft and barrier hydrated in saline and inserted in the sites to restore full alveolar height and width.




4 Primary closure obtained and maintained through the course of healing under a fixed transitional restoration.



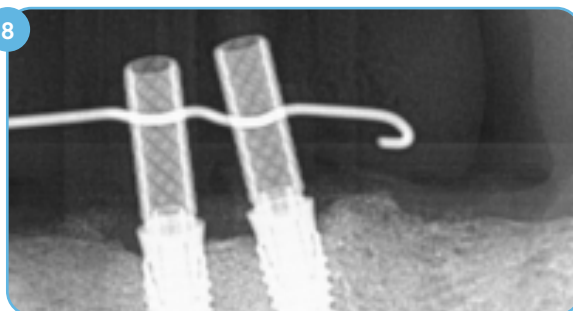
5 At seven months, full thickness flaps were elevated revealing significant improvement in alveolar height and width.



6 Two dental implants were placed in ideal locations for screw-retained restorations.



7 Histologic analysis of the retrieved core shows 42% vital bone and 15% graft.



8 Postoperative radiograph of implants in place.

Ordering Information

Small Particles

Item No.	Description
ROXR05	RegenerOss Resorbable Xenograft, 250 - 1000 μm , 0.5 cc
ROXR10	RegenerOss Resorbable Xenograft, 250 - 1000 μm , 1.0 cc
ROXR20	RegenerOss Resorbable Xenograft, 250 - 1000 μm , 2.0 cc
ROXR40	RegenerOss Resorbable Xenograft, 250 - 1000 μm , 4.0 cc

Shelf-life: Three (3) years

Large Particles

Item No.	Description
ROXRLG10	RegenerOss Resorbable Xenograft, 1000 - 2000 μm , 1.0 cc
ROXRLG20	RegenerOss Resorbable Xenograft, 1000 - 2000 μm , 2.0 cc

Shelf-life: Three (3) years

Syringe Delivery - Small Particles

Item No.	Description
ROXRS025	RegenerOss Resorbable Xenograft, Syringe, 250 - 1000 μm , 0.25 cc
ROXRS05	RegenerOss Resorbable Xenograft, Syringe, 250 - 1000 μm , 0.5 cc

Shelf-life: Two (2) years



For more information, visit [ZimVie.com](https://www.zimvie.com)

ZimVie Dental
4555 Riverside Drive
Palm Beach Gardens, FL 33410



Unless otherwise indicated, as referenced herein, all trademarks and intellectual property rights are the property of ZimVie Inc. or an affiliate; and all products are manufactured by one or more of the dental subsidiaries of ZimVie Inc. (Biomet 3i, LLC, Zimmer Dental, Inc., etc.) and marketed and distributed by ZimVie Dental and its authorized marketing partners. MatrixOss is a trademark of Collagen Matrix, Inc. MatrixOss is marketed as RegenerOss Xenograft by ZimVie. Osstell is a trademark of Osstell AB. For additional product information, please refer to the individual product labeling or instructions for use. HTIRW is manufactured by Elos Medtech Pinol A/S and distributed by ZimVie Dental. Product clearance and availability may be limited to certain countries/regions. This material is intended for clinicians only and does not comprise medical advice or recommendations. Distribution to any other recipient is prohibited. This material may not be copied or reprinted without the express written consent of ZimVie. ZV1910 REV A 11/23 ©2023 ZimVie. All rights reserved.

